

## The Utility of Calretinin Immunohistochemistry in the Diagnosis of Hirschsprung's Disease

Safa Majid Khudhair\*, Adil Rabea Al Saadawi\*\*

### ABSTRACT:

#### BACKGROUND:

Hirschsprung's disease (HD) is a congenital intestinal motility disorder with absence of ganglion cells in the colonic wall, Diagnosis of the disease is based primarily on histopathological analysis, but in this respect, there are limitations associated with standard histology and histochemistry. Calretinin immunohistochemistry (IHC) was implemented to solve the diagnostic problems of this disease as a diagnostic marker.

#### OBJECTIVE:

We aimed to test, identify and compare the immunostaining calretinin in the aganglionic segment of colon specimens and to assess the diagnostic importance of the process with the normoganglionic segment (control group).

#### PATIENTS AND METHODS:

The specimens contained 40 patients with HD histopathology and 20 others (as a control group) who were colectomized for other reasons, 60 paraffin wax blocks were analyzed for full-blown bowel specimens and rectum biopsy. Sixty (paraffin wax) blocks of full bowel thickness and rectal biopsy were examined. In IHC stained slides, calretinin immunoreactivity and pattern of stain for ganglion cells (nuclear and cytoplasmic) and nerve fibers in different bowel layers were assessed.

#### RESULTS:

Calretinin Immunostaining was positive of ganglion cells (nuclear and cytoplasmic staining) and nerve fibers in the mucosa (lamina propria), submucosa and muscularis propria in all specimens of control group except one case (2.5 percent), calretinin immunoreactivity of ganglion cells and nerve fibers was negatively (-), In aganglionic segments (case group). This method had sensitivity of 97.5% and specificity of 100% for diagnosis of HD. The positive predictive value was 100% and negative predictive value was 95.2%.

#### CONCLUSION:

Immunohistochemistry Calretinin can be used for the diagnosis of HD as a dependable and ancillary method.

**KEYWORDS:** Hirschsprung Disease, Calretinin, Immunohistochemistry.

### INTRODUCTION:

Hirschsprung's disease (HD) also known as congenital megacolon, is a unique enteric nervous system malformation marked by lack of submucosal (Meissner) and myenteric (Aurbach) submucosal nerve plexuses of distal colonic wall<sup>(1-4)</sup>. In 5000 liveborns, 1 is affected. It is considered in the differential diagnosis of patients with severe constipation at any age, especially in the pediatric age group<sup>(5)</sup>. HD Etiology is not defined specifically, but is assumed to be correlated with defects in craniocaudal ganglion cell migration during intestinal development<sup>(1,2)</sup>.

The diagnosis is based on clinical data, imaging studies and histological features together. The diagnosis of HD before surgery is determined by the rectal biopsy.<sup>(2,3,5)</sup>

But the detection of ganglion cells or evidence that ganglion cells are missing requires multiple serial cuts and time consumption, also many falls. therefore, a number of auxiliary methods have been developed for diagnosing HD, such as acetyl cholinesterase (AChE) histochemistry and several IHC markers<sup>(1,5)</sup>. AChE does have several drawbacks since it needs new frozen fresh tissue and high rates of interobserver discord and high false positive and false negative outcomes are also present, Calretinin has recently been Introduced as a useful HD diagnostic marker<sup>(5)</sup>.

\* Al-Wasiti Teaching Hospital, Baghdad- Iraq

\*\* Teaching Laboratories- Medical City, Baghdad/Iraq



## Hirschsprung's Disease

HD was claimed to be characteristic of lack of expression calretinin in the colonic wall.

### PATIENTS AND METHODS:

This is a cross-sectional study that was carried out in Baghdad Medical City-Teaching Laboratories (covering the period from February 2016 November 2017), Formalin-fixed tissue blocks of paraffin of full-thick bowel specimens and rectal biopsies for (40) patients with HD diagnosis (10 females, 30 males) were collected and (20) patients that underwent colectomy for other reasons (as control group) were collected from archived materials from Baghdad medical city -teaching laboratories. Patients are between 8 days and 13 years of age.

Two sections of 5  $\mu$ m thickness were taken from each block, the first one for histological revision was stained with hematoxylin and eosin stain (H&E), Immunohistochemically Calretinin was stained in the other section.

Hematoxylin eosin staining and calretinin Immunohistochemistry slides have been stained with hematoxylin and eosin procedure to confirm the initial diagnosis has again been confirmed. After the technique of Avidin-Biotin peroxidase, immunostaining was performed on paraffin blocks from the pathology archive.

The IHC slides have been handled as follows: first 4  $\mu$ m sections have been collected and fixed with polyelazine on the slides. The slides were then dewaxed and rehydrated; the primary monoclonal antibody (Dako, clone DAK Calret 1) was incubated.

Result estimation (staining pattern)<sup>(6)</sup>:- Calretinin immunostaining was scored as either positive or negative □ The location of staining (The lamina propria and submucosa nerve fibers or submucosa and muscularis propria ganglion cells have been reported.) Calretinin was considered as positive if any of the specific findings below were present:

- 1) Intensive granular staining of nerve fibers in the lamina propria and submucosa, muscularis propria.
- 2) Diffuse intense nuclear or cytoplasmic staining in meissner or myenteric plexuses

### RESULTS:

Age and Gender The distribution of study patients by age is shown in figure(1), The mean age of the sample groups was not statistically significant ( $P=0.526$ ). In this study, the highest proportion of study patients in case group and control group was found in age group 1 – 5 years (45%).

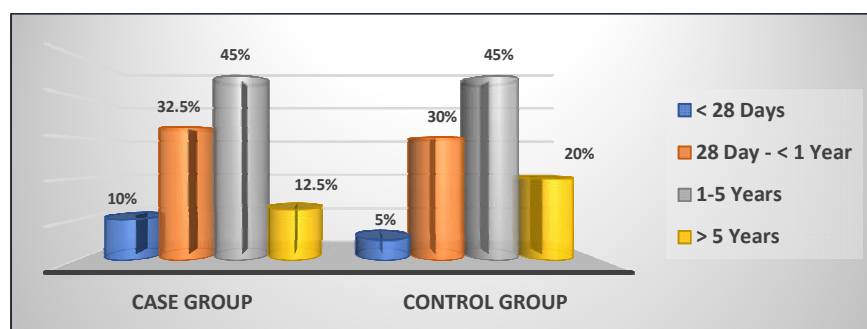


Figure 1: Distribution of study patients by age

Figure 2 shows the distribution of study groups by gender. In this study, proportion of males was higher than females in case and control groups

(75% versus 25% and 60% versus 40% respectively) with a male to female ratio in case group of 3:1.



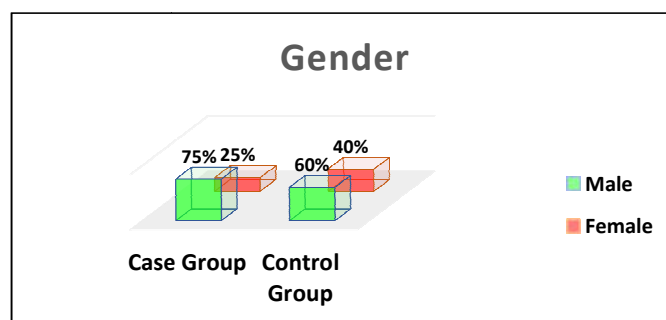


Figure 2: Distribution of study groups by gender

Table 1 shows the sensitivity, specificity and accuracy of calretinin IHC. The results of Calretinin IHC conform with the H&E stains

Table (1): Sensitivity, Specificity and Accuracy of calretinin IHC

Calretinin IHC	H & E Staining		Total
	Hirschsprung disease	No Hirschsprung disease	
Hirschsprung disease	39	0	39
No Hirschsprung disease	1	20	21
Total	40	20	60

Table 2: Values of Sensitivity, Specificity and Accuracy of calretinin IHC

Sensitivity	Specificity	Accuracy	PPV	NPV
97.5%	100%	95.2%	100%	95.2%

NPV: negative predictive value, PPV: positive predictive value

There was case a 3-month-old girl with small rectal biopsy(0.3cm) show pattern of immunostaining in the ganglionic cells and INFs similar to control group(figure 5) This can suggest that ganglion cell maturation is incomplete at the time of birth, particularly in the submucosal region, so H&E staining can make it difficult to identify these cells and can be readily confused with endothelial cells and plasma cells among others

It is interesting to note that we found in 4 of our (HD)cases some immunoreactive axons demonstrated punctate (rather than confluent) staining in some hypertrophic nerve of the submucosa and muscularis mucosa nerve fibers but with no evidence of ganglion cell staining figure ( 6) 4 patients' biopsies had certain characteristics that represented potential pitfalls for diagnosis.

We expected, as indicated by previous studies, that a positive staining with the calretinine

antibody was strictly associated with the presence of ganglion cells in submucosae and that calretinine immunostaining was always negative in nerve fibers in HD. Part of this hypothesis seemed to be false, As calretinine immuno-histochemistry, certain nerve fibers may be slightly positive but not tinted (i.e., muscular mucosae, lamina propria, or nuclear staining) with authentic HD.

## Samples from cases and figures:

Figure 3: control cases normal colonic biopsy (A)normally occurring myenteric plexus (Auerbach's plexus) ganglion cells (X40). (B) & (C)normal staining pattern of calretinin for ganglion cells, Strong brown cytoplasmic and nucleus stain shows calretinin immunoreactivity, In lamina propria, submucosa and muscularis propria. (D) calretinin staining myenteric plexus (Auerbach's plexus), Strong brown confluent cytoplasm stain(X10).



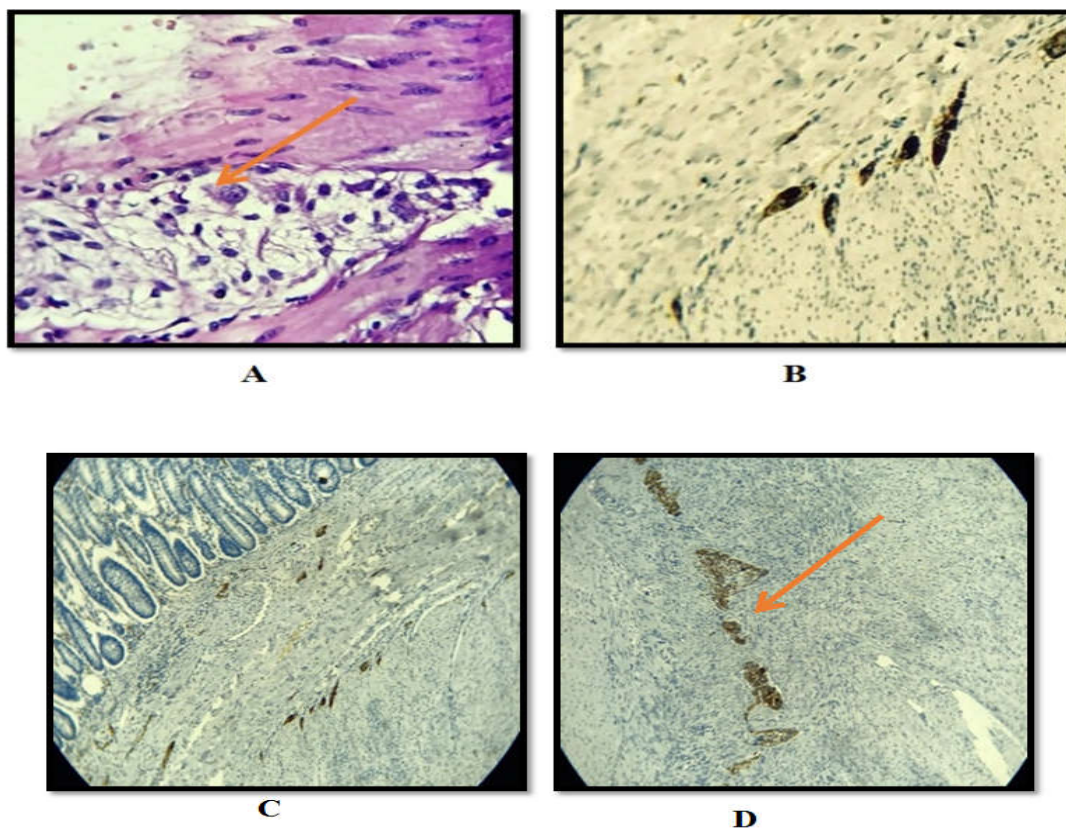


Figure 3

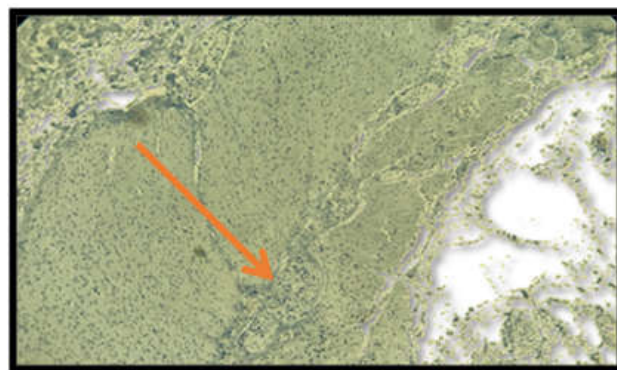


Figure 4: Low Power View of Full Wall Thickness Section Shows no Calretinin Immunoreactivity in ganglion cells and intrinsic nerve fibers(Lamina Propria, Submucosa and Muscularis Propria nerve hypertrophy)(X10).



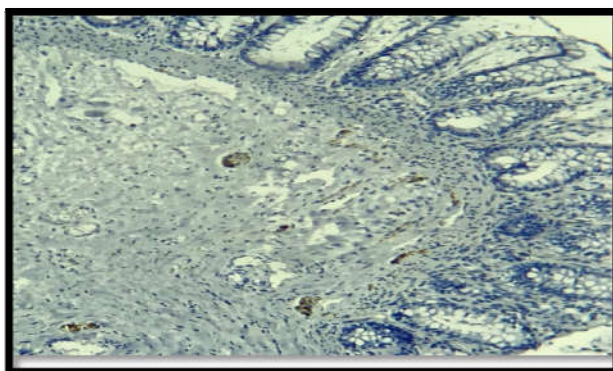


Figure 5: strong cytoplasmic and nuclear calretinin immunoreactivity in ganglion cells and nerve fibers of sub mucosa.(X10)

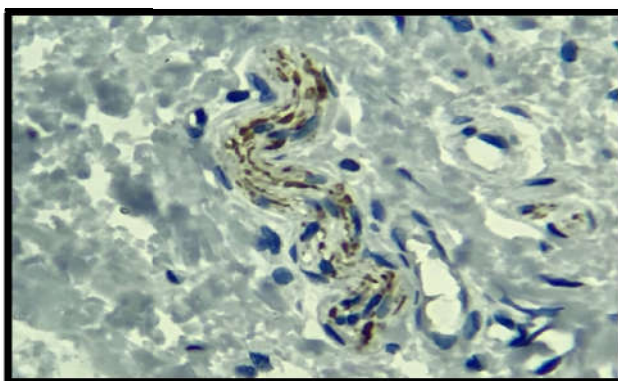


Figure 6: biopsy of rectum with HD. There is punctate (rather than confluent) immunoreactivity in a deep submucosal hypertrophied nerve interpreted as a pitfall stain.(X40)

### DISCUSSION:

The male to female ratio is generally reported (4:1) (Ashcraft KW, 2004)<sup>[8]</sup>. Klein et al (1993)<sup>[9]</sup>, reported male to female ratio (3.3:1). In this study it's nearly the same (3:1).

With mean age of  $2.5 \pm 3.28$  years ranging from 8 days to 13 years which goes with mehran hiradfar et al (2012)<sup>(10)</sup> which was (17) months and much higher than Rouzrokh et al<sup>(11)</sup> which was (3.6) months, due to delayed diagnosis and referral to paediatric surgery center also because we have some cases with late presentation at the age of 13 years.

In this study immunoreactivity in nerve fibers showed variable intensity, granular and fibrillar staining in the lamina propria, sub-mucosa and muscularis propria.

This result was compatible with the study of Kacar et al (2011) and Anbardar et al (2015) they found calretinin positivity in nerve fibers

was one of an intense granular reactivity. The granules crowded and showed a heterogeneous staining pattern.

According to this study, Ganglion cells mostly showed intense granular cytoplasmic and nuclear staining both in submucosa and muscularis propria. These results were in agreement with the study of: Anbardar MH et al<sup>12</sup> which recommend the use of calretinin in posterior myectomy specimens to find ganglion cells, and Rakhshani et al (2016).

There was case of patients group (HD) show pattern of immunostaining in the ganglionic cells and INFs similar to control group. And these results were in agreement with the study of: Barshack et al (2004), Kapur et al (2009)<sup>13</sup> Guinard-Samuel et al (2009)<sup>14</sup> Rakhshani et al (2016)<sup>7</sup>.



## Hirschsprung's Disease

In this study 4 group of patients with biopsies (HD) had certain characteristics that were possible diagnostic pitfalls. This finding has been documented previously by Barshack et al (2004), Kapur et al (2009), Guinard-Samuel et al (2009)<sup>14</sup>, hiradfar et al (2012), and kacar et al (2012). They identified a potential pitfall of 'slight faint positive staining of some nerve fibers in HD', and suggested that this could indicate the beginning of a transitional zone between aganglionic and ganglionic bowel and suggested To avoid this potential and exceptional pitfall calretinine should be used, following standard histology.

### CONCLUSION:

In conclusion, the results of this study showed that calretinin IHC in patients suspected of having HD is a very effective, reliable, sensitive and accurate technique to detect aganglionosis. The use calretinin on HD patient specimens can help with accurate diagnosis, decrease the need for repeat biopsy and serial block sectioning. Interpretation of calretinin IHC is easy and simple and does not need especial experience. Binary pattern of interpretation (negative or positive) and the interpretation must be association with clinical data and H and E stained sections.

### RECOMMENDATION:

Should be routinely used calretinin IHC as an additional tool in diagnosis HD, particularly because in many laboratories which is not specialized in pediatric pathology, and to confirm or rule out diagnosis of HD to avoid patient complication of aganglionic magacolon and surgery .

### REFERENCES:

1. Gera- izadeh B, Akbarzadeh E, Izadi B, Foroutan HR, Heidari T. Immunohistochemical study of enteric nervous system in hirschsprung's disease and intestinal neuronal dysplasia. *Histol His- topathol.* 2013;28(3):345-347.
2. Kapur RP. Practical pathology and genetics of Hirschsprung's disease. *Semin Pediatr Surg* 2009; 18:212-223.
3. Kaçar, A., Arikok, A.T., Azili, M.N., Ekberli Agirbas, G. & Tiryaki, T. Calretinin immunohistochemistry in Hirschsprung's disease: An adjunct to formalin-based diagnosis. *Turk J Gastroenterol*(2012),23:226-33
4. Kapur RP. Can we stop looking? Immunohistochemistry and the diagnosis of Hirschsprung disease. *Am J Clin Pathol.* 2006;126(1):9.
5. Singh SJ, Croaker GD, Manglick P, Wong CL, Atha- nasakos H, Elliott E, et al. Hirschsprung's disease: the Australian Paediatric Surveillance Unit's experience. *Pediatr Surg Int.* 2003;19:247-251.
6. Shamsuddin AM, Phelps PC, Trump BF. Human large intestinal epithelium: light microscopy, histochemistry, and ultrastructure. *Hum Pathol.* 1982;13(9):790-803.
7. Rakhshani N, Araste M, Imanzade F, Panahi M, Safarnezhad Tameshkel F, Sohrabi MR, et al. Hirschsprung Disease Diagnosis: Calretinin Marker Role in Determining the Presence or Absence of Ganglion Cells. *Iran J Pathol* 2016; 11(4):409-415.
8. The loss of calretinin expression indicates aganglionosis in Hirschsprung's disease. arshack I, Fridman E, Goldberg I, Chow- ers Y, Kopolovic J. *J Clin Pathol.* 2004;57(7):712.
9. Klein MD, Philippart AI. Hirschsprung's disease three decades experience at a single institution, *J Pediatr Surg* 1993,28 (10) 41291-3.



10. Hiradfar M, Shari N, Khajedaluee M, Zabolinejad N, Taraz Jamshidi S. Calretinin immunohistochemistry: an aid in the diagnosis of Hirschsprung's disease. Iran J Basic Med Sci 2012;15(5):1053-9.
11. Mohsen Rouzrokh , MD ; Farzaneh Jadali, MD ; Atoosa Gharib, MD ; Ahmad Khaleghnejad-Tabari , MD ; Azita Tavassoli , MD ; Leily Mohajerzadeh , MD : Iran J PEDIATR March 2011;vol 21 ( no 1) , Pp:72-70.
12. Mohammad Hossein Anbardar ; Bita Geramizadeh , Hamid Reza Foroutan, et al Evaluation of Calretinin as a New Marker in the Diagnosis of Hirschsprung Disease. Iran J Pediatr. 2015;25(2):e367 .
13. Kapur, R.P. et al. Calretinin immunohistochemistry versus acetylcholinesterase histochemistry in the evaluation of suction rectal biopsies for Hirschsprung Disease. Pediatr Dev Pathol, 2009;12, 6-15.
14. Guinard-Samuel V, Bonnard A, De Lagausie P, Philippe-Chomette P, Alberti C, El Ghoneimi A, et al. Calretinin immunohistochemistry: a simple and efficient tool to diagnose Hirschsprung disease. Mod Pathol 2009; 22:1379-1384.